

IMPACT OF PHYTOESTROGENS ON ENDOCRINE GLANDS OF ALBINO RATS I. PITUITARY

EMMA R. SERAPHIM* AND M. P. SINHA

Department of Zoology, Nirmala College, Ranchi - 834 002

Department of Zoology, Ranchi University, Ranchi - 834 008

E-mail: seraphim.emmarani4@gmail.com

KEY WORDS

Phytoestrogen
Citrus medica

Received on :
24.08.2009

Accepted on :
11.01.2010

*Corresponding
author

ABSTRACT

Studies have been conducted to determine the impact of estrogenic activities of ethanolic extract of seeds of *Citrus medica* on pituitary gland of albino rats. Histological preparations by differential staining pituitary gland of extract treated sexually immature and ovariectomised female albino rats are observed under light microscope on the basis of the tinctorial response of different cells. The increased uterine weight and highly developed uterine glands proved the estrogenic activity of the ethanolic extract of the seeds of *Citrus medica*. Pars distalis of pituitary gland of control rats showed presence of significant number of STH cells and moderate number of LTH cells (acidophils). A number of gonadotrophs were observed. Thyrotrophs were scattered throughout the pars distalis and were found mainly present towards the periphery while the pars distalis of ethanolic extract of treated rats showed insignificant changes in the number of acidophils STH and LTH. Thyrotrophs were granulated and scattered throughout the pars distalis. The numbers of gonadotroph FSH were significantly increased.

INTRODUCTION

Environmental chemicals also have oestrogenic effects. Both on aquatic and terrestrial life including humans may obtain it from two main sources, either from plants called phytoestrogen and synthetic oestrogen.

The naturally occurring phytochemicals in plants and plant products which are structurally and functionally similar to 17- β oestradiol which is natural oestrogen involved in the development and function of male and female genital tract neuroendocrine tissues, bone and breast are the phytoestrogen (Burton and Wells, 2002).

The principle phytoestrogens isoflavones (coumestrol, genistein, daidzein and equol) and lignin (enterolactone and enterodiol) are low molecular weight diphenolic antimicrobial compound (phytoalexin) synthesized de novo in plants in response to exposure to bacterial pathogens and may exert their biological activity by (i) mimicking the action of endogenous oestrogen (ii) acting as oestrogen antagonists (iii) altering the pattern of synthesis and metabolism of endogenous hormone (iv) modifying hormone receptor levels (Burton and Wells, 2002).

Even a low dose phytoestrogen diet can induce developmental and maturational abnormalities in both laboratory animals and domestic livestock and can affect human health too. (Fredrick et al., 1981, Schinckel, 1948)

Among their widespread clinical effects dietary phytoestrogens are purported to reduce the risk of cancer, have antioxidant and free radical scavenger activity, reduce serum cholesterol, induce cell differentiation and inhibit angiogenesis in human. (Sharangouda and Patil, 2006 and Cline and Hughes, 1998) to estrogens can be present in the herbs used for treatment for

many diseases (unconventionally), in the diet in legumes, grains, nuts, fruits and other fiber rich foods (Humfrey, 1998 and Wilcox et al., 1990).

The paper reports the impact of estrogenic activities of ethanolic extract of seeds of *Citrus medica* on pituitary gland of Wister strain albino rats on the basis of histological study.

MATERIALS AND METHODS

The fresh seeds of *C. medica* collected from fruits and shed dried were powdered after identification and authentication. Green gummy ethanol extracts were prepared with help of Soxhlet apparatus and stored at 6°C in refrigerator.

Colony bred Wister strain immature female, 30 days old, weighing 35-40g were used. The animals were subjected to bilateral ovariectomy by dorsolateral approach under light anaesthesia and semi-sterile condition and divided into two groups, each having 6 animals.

Group I: Control, received 0.2mL Tween-80(1%) for 7days.

Group II: Treated, received 200mg ethanol extract of seeds of *C. medica* / kg body weight in 0.2mL Tween-80(1%) orally for 7days.

Twenty four hours after the final treatment rats were sacrificed by decapitation. At necropsy the uteri and pituitary glands were dissected out, freed from extraneous fat and connective tissues. Uteri were fixed in alcoholic bouins for 24 hrs. The tissues were transferred to 70% alcohol and after giving two changes of 70%, these tissues were dehydrated and cleared in xylol and embedded in paraffin wax (58-59°C).

Pituitary gland was washed and fixed in formal sublimate for 24 hrs and there after washed under running tap water for 24

hrs. The tissues were dehydrated in graded alcohol, cleared in xylol and embedded in paraffin wax (58-59°C).

The prepared blocks were sectioned at 3 μ and 5 μ respectively. A battery of histochemical techniques to distinguish different cell types of adenohypophyses of pituitary gland (Table 1) was used while hematoxylin and eosin were used to stain uteri.

RESULTS

In the present investigation efforts have been made to investigate impact of ethanolic extract of the seeds of *C. medica* on the pituitary gland to find out its possible oestrogenic activity.

Pars distalis is the part of pituitary gland which is made up of a large number of anastomosing cords of cells that are mainly responsible for secretion of hormones regulating growth and reproduction (Seraphim, 2009).

Six types of cells are identified on the basis of their shape and tinctorial affinities in both extract treated and control rats. The different cell types of pars distalis are marked with Roman figures according to the classification of Ezrin (1663) and functional designation are as proposed by International nomenclature committee of Von Oordt (1965).

Cell type I: STH

These cells stained orange with orange G and are most common cell type in pars distalis. These are generally round to oval in shape with eccentrically placed round nuclei and numerous rounds to oval shaped secretory granules. There is no change in the structure and number of STH cells in the extract treated rats compared to control (Fig. 1 and 2).

Cell type II: LTH

LTH or lactotrophs stained orange red with PAS/OG, red with Mallory's trichome. These are round or oval with irregular cell boundary. Apart from their tinctorial affinities LTH cells can be recognized by the pronounced changes which these cells undergo during the different phases of the reproductive cycle. These cells in treated immature rats show no significant changes in comparison to control (Fig. 1 and 2).

Cell Type III: ACTH

These cells are selectively stained with lead haematoxylin (Mac. Conail, 1947) in blue black colour in control. The cells have oval or irregular shape with long cytoplasmic processes. The observation shows that the no of these cells increases in treated rats (Fig. 3 and 4).

Cell Type IV: TSH

Thyrotroph cells are stained blue with Mallory's trichome, PAS/MB/OG and by PAS/OG in control. These are oval, angular, polyhedral or triangular in shape showing distinct boundaries. These are distributed throughout the gland specially towards peripheral region in control. In treated rats there is no significant change in the number of TSH cells but they appear active as some are granulated and some are partially degranulated (Fig 1 and 2).

Cell Type V: LH

LH or leuteinizing hormone cells are stained purple red with

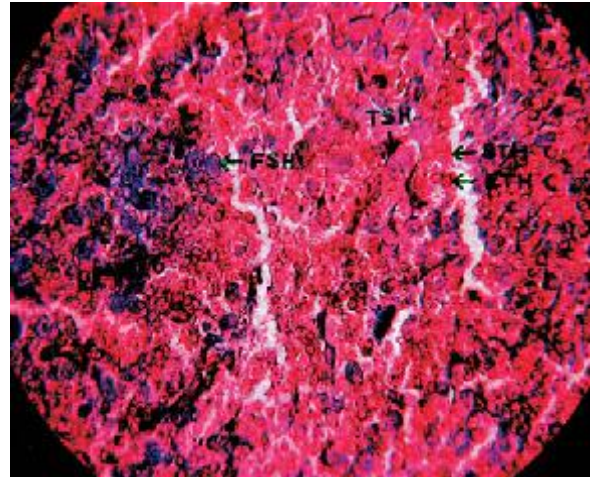


Figure 1: Pituitary gland of control rat showing STH, LTH, FSH, TSH cells, stained with Crossman x 100

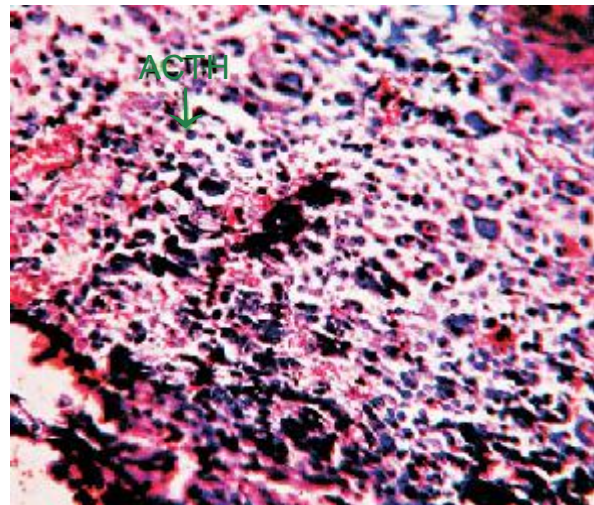


Figure 2: Pituitary gland of experimental rat showing STH, LTH, FSH, TSH cells, stained with Crossman x 100

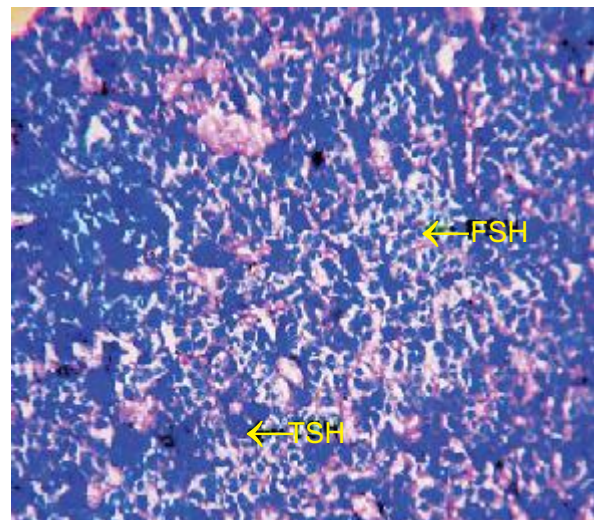


Figure 3: Pituitary gland of control rat showing ACTH cells stained with lead-hematoxylin method of Mac-Conaill x 100

Table 1: Tinctorial affinities of the cell types in the pars distalis of albino rats

Staining Technique	Pars Distalis ISTH	II LTH	III ACTH	IV TSH	V LH	VI FSH
Mallory's Trichome Technique modified after Crossman's (1937)	Orange	Red	–	Faint Blue	Faint Blue	Faint Blue
PAS / OG	Orange	Orange	Red	–	Red	Red
MB / PAS / OG (Wilson Ezrin)	Orange	Orange	Red	–	Red	Purple Blue
Lead hematoxylin	–	–	BlueBlack	–	–	–

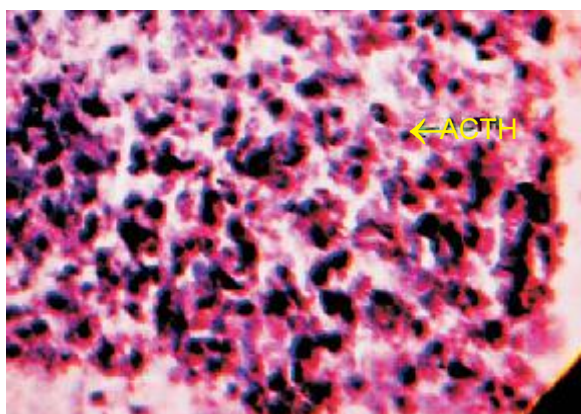


Figure 4: Pituitary gland of experimental rat showing ACTH cells, stained with lead hematoxylin method of Mac-conaill x 100

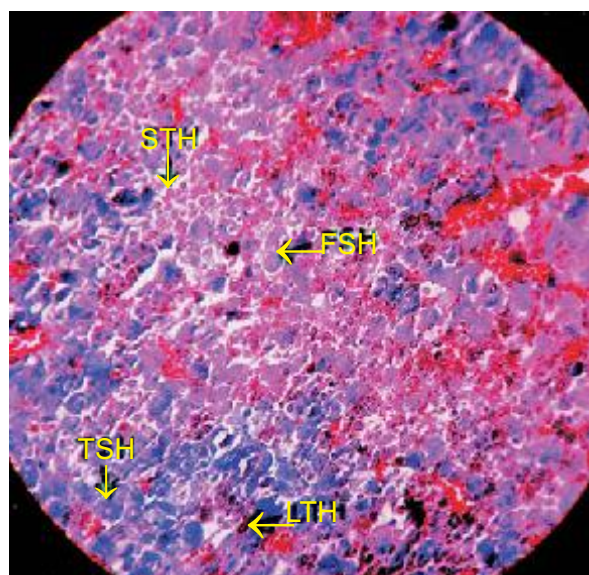


Figure 5: Pituitary gland of experimental rat showing fsh cells stained with PAS/MB/OG x 100

PAS/MB/OG, yellow red with PAS/OG and faint blue with mallory's trichome method modified after Crossman (1960). These cells could be identified by combined histochemical reaction of MB/PAS/OG. They are PAS positive and weakly stained with MB so they appear purple blue in colour. In control rats their number is few and there is no significant change in their number in treated animal.

Cell Type VI: FSH

FSH or follicle stimulating hormone cells are stained faint blue by Mallory trichome modified after Crossman (1960), purple

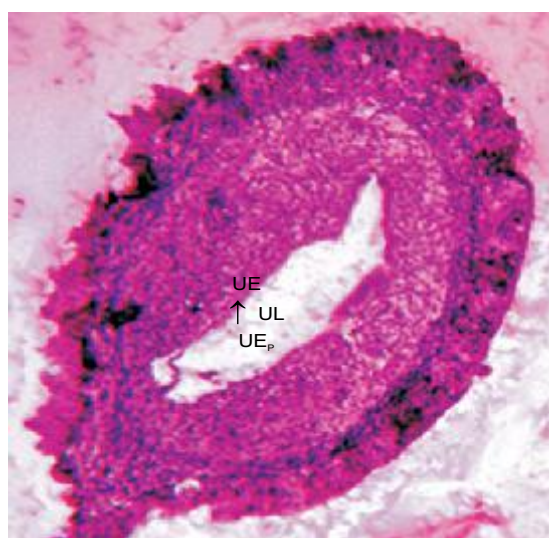


Figure 6: Uterus of control stained with hematoxyline and eosin x 450. UL: Uterine Lumen, UEp: Uterine Epithelium, UE: Uterine Endometrium

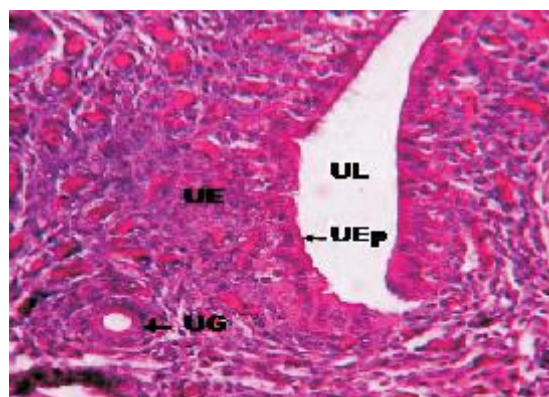


Figure 10: Uterus of experimental rat showing well developed uterine glands, stained with hematoxyline and eosin x 450. ul : uterine Lumen, UEp: Uterine Epithelium, UE : Uterine Endometrium, UG : Uterine Gland

red in combined histochemical technic PAS/MB/OG and PAS/OG in control. These are scattered throughout the pars distalis. Increase in the number and hypertrophy in FSH cells occur in treated rats (Fig. 1, 2 and 5).

DISCUSSION

The presented facts strongly indicate estrogenic activity of ethonolic extract of seeds of Citrus medica as the master endocrine gland - pituitary responds to it positively by showing hypertrophy and significant increase in numbers of FSH cells,

(Whitten *et al.*, 1993). There is an insignificant increase in the number of LTH and ACTH cells showing effect of phytoestrogenic diet on mammary gland and adrenal gland respectively, (Whitten *et al.*, 1995, Wilcox *et al.*, 1990 and Sturgis Mc Keever, 1959, 1964).

These findings are strongly supported by observation of stained uterine sections that shows enhanced luminal epithelium and highly developed uterine glands induced due to the estrogenic effect of extracts of seeds of citrus medica (Fig. 6 and 7). The present finding is in agreement with those of Bhargava (1984) and Sharangouda and Patil (2006).

The study of other endocrine glands like thyroid and adrenal glands support the findings of the present project work (Seraphim, 2010).

CONCLUSION

On the basis of the study conducted it can be safely concluded that the seeds of Citrus medica contain sufficient amount of phytoestrogen which can be used as a potential source of this hormone and could be utilized for beneficial purpose.

ACKNOWLEDGEMENT

The first author acknowledges the financial support by UGC, ERO Kolkatta (Project No. F. PSJ-003/08-09).

REFERENCES

- Bhargava, S. K. 1984.** Estrogenic and pregnancy interruptory effects the flavonoides of Vitex negundo seeds in mice. *Plant. Med. Phytotherap.* **18**: 74-79.
- Burton, J. L. and Wells, M. 2002.** The effects of Phytoestrogens on the female genital tract. *J. Clin. Pathol.* **55**: 401-407.
- Cline, J. M. and Hughes, C. L. jr. 1998.** Phytochemicals for the prevention of breast and endometrial cancer. *Cancer Treat. Res.* **94**: 107-134.
- Fredricks, G. K., Kincaid, R. L., Bondioli, K. R. and Wright, R. W. 1981.** Ovulation rates and embryo degeneracy in female mice fed the phytoestrogen, coumestrol. *Proc. Soc. Exp. Biol. Med.* **167**: 237-241
- Humfrey, C. D. 1998.** Phytoestrogens and human health effects: weighing up the current evidence. *J. Natural Toxins.* **6**: 51-59.
- Mac Conail, M. A. 1947.** *J. Anat.* **81**: 371.
- Schinckel, P. G. 1948.** Infertility in ewes grazing subterranean clover pastures. Observations on breeding following transferred to sound. Country. *Austr. Veter. J.* **24**: 289-294.
- Seraphim, E. R. 2009.** Endocrine interaction during different phases of the female reproductive cycle in *Hipposideros lankadiva* (Kelaart). *The Bioscan.* **4(1)**: 143-148.
- Seraphim, E.R. 2010. Project report submitted to U.G.C., ERO, Kolkata(Project No. PSJ-003/08-09. pp. 4-6.
- Sharangouda and Patil, S. B. 2006.** Oxalis corniculata (whole plant) extracts exhibit estrogenic activities in wistar strain albino rats. *The Bioscan.* **1(1-4)**: 63-67.
- Sturgis Mc Keever 1959.** Effects of reproductive activity on the weight of adrenal glands in *Microtus montanus*. *Ant. Reco.* **135**: 279.
- Sturgis Mc Keever 1964** Variation in the wt. of the adrenal, pituitary and thyroid gland of the white-footed mouse *Peromyscus maniculatus*. *Am. J. Anat.* **114**: 1-7
- Von Oordt P. G. W. J. 1965.** Nomenclature of the hormone producing cell in the adenohippophysis. *Gen. Comp. Endocrinol.* **5(1)**: 131-134.
- Whitten, P. L., Lewis, C. and Naftolin, F. A. 1993.** Phytoestrogen diet induces the premature anovulatory syndrome in lactationally exposed female rats. *Biol. Reprod.* **49**: 1117-1121.
- Whitten, P. L., Lewis, C., Russel, E. and Naftolin, F. 1995.** Phytoestrogen influences on the development of behaviour and gonadotropin function. *Proc Soc. Exp. Biol. Med.* **208**: 82-86.
- Wilcox, G., Wahlgrist, M. L., Bueger, H. G. and Medley, G. 1990. Oestrogenic effects of plant foods in postmenopausal women. *Br. Med. J.* **301**: 905-906.